



Protocol for the Examination of Specimens from Patients With Carcinoma of the Distal Extrahepatic Bile Ducts

Version: 4.2.0.0

Protocol Posting Date: June 2021

CAP Laboratory Accreditation Program Protocol Required Use Date: March 2022

The changes included in this current protocol version affect accreditation requirements. The new deadline for implementing this protocol version is reflected in the above accreditation date.

For accreditation purposes, this protocol should be used for the following procedures AND tumor types:

Procedure	Description
Local or Segmental Bile Duct Resection	Includes Local or Segmental Bile Duct Resection and Pancreaticoduodectomy (Whipple resection)
Tumor type	Description
Carcinoma	Invasive carcinomas including small cell and large cell (poorly differentiated) neuroendocrine carcinoma

This protocol is NOT required for accreditation purposes for the following:

Procedure
Biopsy
Primary resection specimen with no residual cancer (eg, following neoadjuvant therapy)
Cytologic specimens
Intraductal papillary neoplasm without associated invasive carcinoma
Mucinous cystic neoplasm without associated invasive carcinoma

The following tumor types should NOT be reported using this protocol:

Tumor type
Well-differentiated neuroendocrine tumors of distal extrahepatic bile duct
Lymphoma (consider the Hodgkin or non-Hodgkin Lymphoma protocols)
Sarcoma (consider the Soft Tissue protocol)

Authors

Lawrence J. Burgart, MD*; William V. Chopp, MD*; Dhanpat Jain, MD*.

With guidance from the CAP Cancer and CAP Pathology Electronic Reporting Committees.

* Denotes primary author.

Accreditation Requirements

This protocol can be utilized for a variety of procedures and tumor types for clinical care purposes. For accreditation purposes, only the definitive primary cancer resection specimen is required to have the core and conditional data elements reported in a synoptic format.

- Core data elements are required in reports to adequately describe appropriate malignancies. For accreditation purposes, essential data elements must be reported in all instances, even if the response is “not applicable” or “cannot be determined.”
- Conditional data elements are only required to be reported if applicable as delineated in the protocol. For instance, the total number of lymph nodes examined must be reported, but only if nodes are present in the specimen.
- Optional data elements are identified with “+” and although not required for CAP accreditation purposes, may be considered for reporting as determined by local practice standards.

The use of this protocol is not required for recurrent tumors or for metastatic tumors that are resected at a different time than the primary tumor. Use of this protocol is also not required for pathology reviews performed at a second institution (ie, secondary consultation, second opinion, or review of outside case at second institution).

Synoptic Reporting

All core and conditionally required data elements outlined on the surgical case summary from this cancer protocol must be displayed in synoptic report format. Synoptic format is defined as:

- Data element: followed by its answer (response), outline format without the paired Data element: Response format is NOT considered synoptic.
- The data element should be represented in the report as it is listed in the case summary. The response for any data element may be modified from those listed in the case summary, including “Cannot be determined” if appropriate.
- Each diagnostic parameter pair (Data element: Response) is listed on a separate line or in a tabular format to achieve visual separation. The following exceptions are allowed to be listed on one line:
 - Anatomic site or specimen, laterality, and procedure
 - Pathologic Stage Classification (pTNM) elements
 - Negative margins, as long as all negative margins are specifically enumerated where applicable
- The synoptic portion of the report can appear in the diagnosis section of the pathology report, at the end of the report or in a separate section, but all Data element: Responses must be listed together in one location

Organizations and pathologists may choose to list the required elements in any order, use additional methods in order to enhance or achieve visual separation, or add optional items within the synoptic report. The report may have required elements in a summary format elsewhere in the report IN ADDITION TO but not as replacement for the synoptic report ie, all required elements must be in the synoptic portion of the report in the format defined above.

Summary of Changes

v 4.2.0.0

- General Reformatting
- Revised Margins Section
- Revised Lymph Nodes Section
- Added Distant Metastasis Section
- Removed pTX and pNX Staging Classification

Reporting Template

Protocol Posting Date: June 2021

Select a single response unless otherwise indicated.

CASE SUMMARY: (DISTAL EXTRAHEPATIC BILE DUCTS)

Standard(s): AJCC-UICC 8

SPECIMEN (Notes [A](#),[B](#))

Procedure

- Pancreaticoduodenectomy (Whipple resection)
 Segmental resection of bile duct(s)
 Choledochal cyst resection
 Other (specify): _____
 Not specified

TUMOR

Tumor Site (select all that apply)

- Common bile duct, extrapancreatic: _____
 Common bile duct, intrapancreatic: _____
 Common bile duct (not otherwise specified): _____
 Other (specify): _____
 Not specified

Histologic Type (Note [C](#))

Adenocarcinoma

- Adenocarcinoma, biliary type (extrahepatic cholangiocarcinoma)
 Adenocarcinoma, intestinal type
 Mucinous adenocarcinoma
 Clear cell adenocarcinoma
 Signet-ring cell carcinoma (poorly cohesive carcinoma)
 Adenosquamous carcinoma
 Mucinous cystic neoplasm with an associated invasive carcinoma

Other carcinoma types

- Squamous cell carcinoma
 Undifferentiated carcinoma
 Large cell neuroendocrine carcinoma
 Small cell neuroendocrine carcinoma
 Mixed neuroendocrine-non-neuroendocrine tumor (Mixed adenoneuroendocrine carcinoma)
 Other histologic type not listed (specify): _____
 Carcinoma, type cannot be determined: _____

+Histologic Type Comment: _____

Histologic Grade (Note [D](#))

- G1, well differentiated
 G2, moderately differentiated
 G3, poorly differentiated
 Other (specify): _____

___ GX, cannot be assessed: _____
___ Not applicable

Tumor Size

___ Greatest dimension in Centimeters (cm): _____ cm
+Additional Dimension in Centimeters (cm): ___ x ___ cm
___ Cannot be determined (explain): _____

Tumor Extent (select all that apply)

- ___ No invasion (carcinoma in situ / high-grade dysplasia)
- ___ Confined to the bile duct histologically
- ___ Invades beyond wall of bile duct
- ___ Invades duodenum
- ___ Invades pancreas
 - ___ Posterior surface
 - ___ Anterior surface
- ___ Vascular bed / groove (corresponding to superior mesenteric vein / portal vein)
- ___ Invades gallbladder
- ___ Invades other adjacent structure(s)
 - ___ Duodenum
 - ___ Ampulla
 - ___ Stomach
 - ___ Gallbladder
 - ___ Omentum
 - ___ Celiac axis
 - ___ Superior mesenteric artery
 - ___ Common hepatic artery
 - ___ Other (specify): _____
- ___ Cannot be determined (explain): _____

Depth of Tumor Invasion

- ___ No invasion (carcinoma in situ / high-grade dysplasia)
- ___ Less than 5 mm
- ___ 5 to 12 mm
- ___ Greater than 12 mm
- ___ Cannot be determined (explain): _____

Lymphovascular Invasion (Note E)

- ___ Not identified
- ___ Present
- ___ Cannot be determined: _____

Perineural Invasion (Note E)

- ___ Not identified
- ___ Present
- ___ Cannot be determined: _____

+Tumor Comment: _____

MARGINS (Note F)

Margin Status for Invasive Carcinoma

All margins negative for invasive carcinoma

+Closest Margin(s) to Invasive Carcinoma (select all that apply)

- Proximal bile duct: _____
- Distal bile duct: _____
- Bile duct: _____
- Radial: _____
- Pancreatic neck / parenchymal: _____
- Uncinate (retroperitoneal / superior mesenteric artery): _____
- Proximal (gastric or duodenal): _____
- Distal (duodenal or jejunal): _____
- Other (specify): _____
- Cannot be determined: _____

+Distance from Invasive Carcinoma to Closest Margin

Specify in Centimeters (cm)

- Exact distance in cm: _____ cm
- Greater than 1 cm

Specify in Millimeters (mm)

- Exact distance in mm: _____ mm
- Greater than 10 mm

Other

- Other (specify): _____
- Cannot be determined: _____
- Not applicable

Invasive carcinoma present at margin

Margin(s) Involved by Invasive Carcinoma (select all that apply)

- Proximal bile duct: _____
- Distal bile duct: _____
- Bile duct: _____
- Radial: _____
- Pancreatic neck / parenchymal: _____
- Uncinate (retroperitoneal / superior mesenteric artery): _____
- Proximal (gastric or duodenal): _____
- Distal (duodenal or jejunal): _____
- Other (specify): _____
- Cannot be determined (explain): _____
- Other (specify): _____
- Cannot be determined (explain): _____
- Not applicable

Margin Status for High-Grade Intraepithelial Neoplasia

All margins negative for high-grade intraepithelial neoplasia

High-grade intraepithelial neoplasia present at margin

Margin(s) Involved by High-Grade Intraepithelial Neoplasia (select all that apply)

- Proximal bile duct: _____
- Distal bile duct: _____
- Bile duct: _____
- Pancreatic neck / parenchymal: _____
- Proximal (gastric or duodenal): _____

- Distal (duodenal or jejunal): _____
- Other (specify): _____
- Cannot be determined (explain): _____
- Other (specify): _____
- Cannot be determined (explain): _____
- Not applicable

+Margin Comment: _____

REGIONAL LYMPH NODES

Regional Lymph Node Status

- Not applicable (no regional lymph nodes submitted or found)
- Regional lymph nodes present
 - All regional lymph nodes negative for tumor
 - Tumor present in regional lymph node(s)

Number of Lymph Nodes with Tumor

- Exact number (specify): _____
- At least (specify): _____
- Other (specify): _____
- Cannot be determined (explain): _____
- Other (specify): _____
- Cannot be determined (explain): _____

Number of Lymph Nodes Examined

- Exact number (specify): _____
- At least (specify): _____
- Other (specify): _____
- Cannot be determined (explain): _____

+Regional Lymph Node Comment: _____

DISTANT METASTASIS

Distant Site(s) Involved, if applicable (select all that apply)

- Not applicable
- Non-regional lymph node(s): _____
- Liver: _____
- Other (specify): _____
- Cannot be determined: _____

PATHOLOGIC STAGE CLASSIFICATION (pTNM, AJCC 8th Edition) (Note G)

Reporting of pT, pN, and (when applicable) pM categories is based on information available to the pathologist at the time the report is issued. As per the AJCC (Chapter 1, 8th Ed.) it is the managing physician's responsibility to establish the final pathologic stage based upon all pertinent information, including but potentially not limited to this pathology report.

TNM Descriptors (select all that apply)

- Not applicable
- m (multiple primary tumors)
- r (recurrent)
- y (post-treatment)

pT Category

- pT not assigned (cannot be determined based on available pathological information)
- pTis: Carcinoma in situ / high-grade dysplasia
- pT1: Tumor invades the bile duct wall with a depth less than 5 mm
- pT2: Tumor invades the bile duct wall with a depth of 5-12 mm
- pT3: Tumor invades the bile duct wall with a depth greater than 12 mm
- pT4: Tumor involves the celiac axis, superior mesenteric artery, and / or common hepatic artery

pN Category

- pN not assigned (no nodes submitted or found)
- pN not assigned (cannot be determined based on available pathological information)
- pN0: No regional lymph node metastasis
- pN1: Metastasis in one to three regional lymph nodes
- pN2: Metastasis in four or more regional lymph nodes

pM Category (required only if confirmed pathologically)

- Not applicable - pM cannot be determined from the submitted specimen(s)
- pM1: Distant metastasis

ADDITIONAL FINDINGS (Note [H](#))

+Additional Findings (select all that apply)

- None identified
- Choledochal cyst
- Dysplasia
- Primary sclerosing cholangitis (PSC)
- Biliary stones
- Other (specify): _____

SPECIAL STUDIES

+Ancillary Studies (specify): _____

COMMENTS

Comment(s): _____

Explanatory Notes

A. Application

Tumors arising in the biliary tree are classified into 3 groups: intrahepatic, perihilar, and distal (Figure 1). Perihilar tumors are defined as those involving the hepatic duct bifurcation or extrahepatic biliary tree proximal to the origin of the cystic duct¹; distal tumors as those lesions arising between the junction of the cystic duct-bile duct and the ampulla of Vater.² This protocol applies only to cancers arising in the distal extrahepatic bile ducts above the ampulla of Vater (Figure 1) and includes malignant tumors that develop in congenital choledochal cysts and tumors that arise in the intrapancreatic portion of the common bile duct. It does not include low-grade neuroendocrine neoplasms (carcinoids) or tumors arising in the ampulla of Vater. Carcinomas arising in the cystic duct are grouped for staging purposes with carcinomas of the gallbladder. Tumors arising within the intrahepatic bile ducts or perihilar bile ducts are classified and staged using the intrahepatic bile duct protocol or the perihilar bile duct protocol. Tumors of the pancreas and ampulla of Vater are classified separately. Tumors arising from intrapancreatic portion of common bile duct can be difficult to distinguish from pancreatic adenocarcinomas. Symmetric tumor growth around the bile duct and presence of biliary intraepithelial neoplasia favors a bile duct origin.³

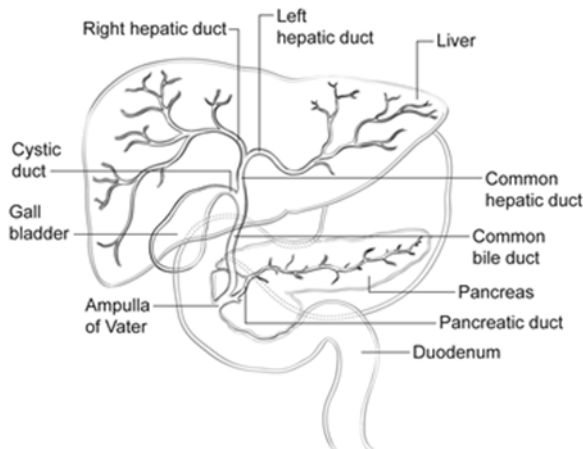


Figure 1. Anatomy of the biliary system.

References

1. DeOliveira ML, Cunningham SC, Cameron JL, et al. Cholangiocarcinoma: thirty-one-year experience with 564 patients at a single institution. *Ann Surg.* 2007;245(5):755-762.
2. Amin MB, Edge SB, Greene FL, et al, eds. *AJCC Cancer Staging Manual.* 8th ed. New York, NY: Springer; 2017.
3. Gonzalez RS, Bagci P, Basturk O, et al. Intrapancreatic distal common bile duct carcinoma: analysis, staging considerations, and comparison with pancreatic ductal and ampullary adenocarcinomas. *Mod Pathol.* 2016;29(11):1358-1369.

B. Choledochal Cyst

Carcinomas may arise in choledochal cysts (congenital cystic dilatation or duplications) of the bile duct. Histologically, they are classified in the same way as those arising in the gallbladder or bile ducts. Stones may be found in these cysts. If dysplasia or carcinoma in situ is found on initial microscopic sections, then multiple additional sections should be examined to exclude invasive cancer in other areas of the cyst.

C. Histologic Type

For consistency in reporting, the histologic classification published by the World Health Organization (WHO) is recommended.¹ However, this protocol does not preclude the use of other systems of classification or histologic types. By WHO convention, the term *cholangiocarcinoma* is reserved for carcinomas arising in the intrahepatic bile ducts (see intrahepatic bile ducts protocol).

Intraductal neoplasms have a relatively favorable prognosis,^{2,3} while signet-ring cell carcinoma, high-grade neuroendocrine carcinomas, and undifferentiated carcinomas are associated with a poorer prognosis.

References

1. WHO Classification of Tumours Editorial Board. *Digestive system tumours*. Lyon (France): International Agency for Research on Cancer; 2019. (WHO classification of tumours series, 5th ed.; vol. 1).
2. Albores-Saavedra J, Murakata L, Krueger JE, Henson DE. Noninvasive and minimally invasive papillary carcinomas of the extrahepatic bile ducts. *Cancer*. 2000;89(3):508-515.
3. Luvira V, Pugkhem A, Bhudhisawasdi V, Pairojkul C. Long-term outcome of surgical resection for intraductal papillary neoplasm of the bile duct. *J Gastroenterol Hepatol*. 2017;32(2):527-533.

D. Histologic Grade

For adenocarcinomas, a quantitative grading system based on the proportion of gland formation in the tumor is suggested and shown below.¹

Grade X	Grade cannot be assessed
Grade 1	Well-differentiated (greater than 95% of tumor composed of glands)
Grade 2	Moderately differentiated (50% to 95% of tumor composed of glands)
Grade 3	Poorly differentiated (less than 50% of tumor composed of glands)

By convention, signet-ring cell carcinomas are assigned grade 3. Undifferentiated carcinomas lack morphologic or immunohistochemical evidence of glandular, squamous or neuroendocrine differentiation. This grading scheme is not applicable to poorly differentiated neuroendocrine carcinomas.

For squamous cell carcinomas, a rare tumor type in the extrahepatic bile ducts, a suggested grading system is shown below. If there are variations in the differentiation within the tumor, the highest (least favorable) grade is recorded.

Grade X	Grade cannot be assessed
Grade 1	Well-differentiated
Grade 2	Moderately differentiated
Grade 3	Poorly differentiated

References

1. WHO Classification of Tumours Editorial Board. *Digestive system tumours*. Lyon (France): International Agency for Research on Cancer; 2019. (WHO classification of tumours series, 5th ed.; vol. 1).

E. Perineural and Vascular/Lymphatic Invasion

Perineural and lymphovascular invasion are common in extrahepatic bile duct carcinomas, although they are found less often in early stage cancers (11%).¹ They should be specifically evaluated because they are associated with adverse outcome on univariate analysis.² Although perineural invasion is sometimes useful for distinguishing carcinoma from non-neoplastic glands, caution should be used in interpretation of this finding in ducts affected by primary sclerosing cholangitis because perineural invasion by benign hyperplastic intramural glands has been reported in this setting³ and in adenomatous hyperplasia.

References

1. Cha JM, Kim MH, Lee SK, et al. Clinicopathological review of 61 patients with early bile duct cancer. *Clin Oncol*. 2006;18(9):669-677.
2. Murakami Y, Uemura K, Hayashidani Y, Sudo T, Ohge H, Sueda T. Pancreatoduodenectomy for distal cholangiocarcinoma: prognostic impact of lymph node metastasis. *World J Surg*. 2007;31(3):337-342; discussion 343-344.
3. Katabi N, Albores-Saavedra J. The extrahepatic bile duct lesions in end-stage primary sclerosing cholangitis. *Am J Surg Pathol*. 2003;27(3):349-355.

F. Margins

Locoregional recurrence, as opposed to distant metastases, is usually the first site of disease recurrence and is often related to residual tumor located in the proximal or distal surgical margins of the bile duct or from tumor located along the dissected soft-tissue margin in the portal area. Local recurrence (usually at the surgical margins) can be attributed in many cases to tumor spread longitudinally along the duct wall and to perineural and lymphovascular invasion.¹

Complete surgical resection with microscopically negative surgical margins is an important predictor of outcome in multivariate analysis for both perihilar and distal bile duct carcinomas.^{2,3}

Malignant tumors of the extrahepatic bile ducts are often multifocal.⁴ Therefore, microscopic foci of carcinoma or intraepithelial neoplasia may be found at the margin(s) even though the main tumor mass has been resected. In some cases, it may be difficult to evaluate margins on frozen-section preparations because of inflammation and reactive change of the surface epithelium or within the intramural mucous glands. If surgical margins are free of carcinoma, the distance between the closest margin and the tumor edge should be measured.

Because 5% of patients with bile duct carcinoma have synchronous carcinomas of the gallbladder, examination of the entire surgical specimen, including the gallbladder, is advised.

References

1. Jarnagin WR. Cholangiocarcinoma of the extrahepatic bile ducts. *Semin Surg Oncol*. 2000;19(2):156-176.
2. DeOliveira ML, Cunningham SC, Cameron JL, et al. Cholangiocarcinoma: thirty-one-year experience with 564 patients at a single institution. *Ann Surg*. 2007;245(5):755-762.
3. Chung YJ, Choi DW, Choi SH, Heo JS, Kim DH. Prognostic factors following surgical resection of distal bile duct cancer. *J Korean Surg Soc*. 2013;85(5):212-218.
4. WHO Classification of Tumours Editorial Board. *Digestive system tumours*. Lyon (France): International Agency for Research on Cancer; 2019. (WHO classification of tumours series, 5th ed.; vol. 1).

G. Pathologic Stage Classification

Surgical resection is the most effective therapy for extrahepatic biliary tract carcinomas, and the best estimation of prognosis is related to the anatomic extent (stage) of disease at the time of resection. In particular, lymph node metastases are predictors of poorer outcome.^{1,2}

For malignant tumors of the distal extrahepatic bile ducts, the TNM staging system of the American Joint Committee on Cancer (AJCC) and the International Union Against Cancer (UICC) is recommended.³ The staging system also applies to tumors arising in choledochal cysts.

According to AJCC/UICC convention, the designation “T” refers to a primary tumor that has not been previously treated. The designation “p” refers to the pathologic classification of the TNM, as opposed to

the clinical classification, and is based on gross and microscopic examination. pT entails a resection of the primary tumor or biopsy adequate to evaluate the highest pT category, pN entails removal of nodes adequate to validate lymph node metastasis, and pM implies microscopic examination of distant lesions. Clinical classification (cTNM) is usually carried out by the referring physician before treatment during initial evaluation of the patient or when pathologic classification is not possible.

Pathologic staging is usually performed after surgical resection of the primary tumor. Pathologic staging depends on pathologic documentation of the anatomic extent of disease, whether or not the primary tumor has been completely removed. If a biopsied tumor is not resected for any reason (eg, when technically infeasible) and if the highest T and N categories or the M1 category of the tumor can be confirmed microscopically, the criteria for pathologic classification and staging have been satisfied without total removal of the primary cancer.

TNM Descriptors

For identification of special cases of TNM or pTNM classifications, the “m” suffix and “y,” “r,” and “a” prefixes are used. Although they do not affect the stage grouping, they indicate cases needing separate analysis.

The “m” suffix indicates the presence of multiple primary tumors in a single site and is recorded in parentheses: pT(m)NM.

The “y” prefix indicates those cases in which classification is performed during or after initial multimodality therapy (ie, neoadjuvant chemotherapy, radiation therapy, or both chemotherapy and radiation therapy). The cTNM or pTNM category is identified by a “y” prefix. The ycTNM or ypTNM categorizes the extent of tumor actually present at the time of that examination. The “y” categorization is not an estimate of tumor before multimodality therapy (ie, before initiation of neoadjuvant therapy).

The “r” prefix indicates a recurrent tumor when staged after a documented disease-free interval and is identified by the “r” prefix: rTNM.

The “a” prefix designates the stage determined at autopsy: aTNM.

T Category Considerations

Tis includes high-grade biliary intraepithelial neoplasia (BillIn-3), intraductal papillary neoplasm with high-grade dysplasia, and mucinous cystic neoplasm with high-grade dysplasia. For intraepithelial lesions, a 3-tier biliary intraepithelial neoplasia classification has been proposed.

The term carcinoma in situ is not widely applied to glandular neoplastic lesions but is retained for tumor registry reporting purposes as specified by law in many states. A synoptic report is not required for intraductal papillary mucinous neoplasms and mucinous cystic neoplasms in the absence of an invasive component. For invasive carcinoma associated with intraductal papillary neoplasms and mucinous cystic neoplasms, the invasive portion can be multifocal. The size of the largest focus as well as cumulative size of all invasive carcinoma foci should be included in the report.

The histology of the extrahepatic biliary tree varies along its length, with little smooth muscle in the wall of the proximal ducts as compared with the distal bile duct. The common bile duct lacks serosa, and the fibromuscular wall is surrounded by fat. Tumor infiltration into the fat beyond the fibromuscular wall is considered as extension beyond the bile duct. These anatomic features make it difficult to assess the anatomic level of tumor invasion. Inflammatory changes in the bile ducts and desmoplastic stromal response to tumor may also cause distortion of tissue boundaries. This has led to change in the T

categories in the AJCC 8th edition, with T1-T3 being defined by the measurement of depth of invasion of tumor. The depth is measured from the basement membrane of adjacent normal or dysplastic epithelium to the point of deepest tumor invasion^{4,5}. Properly oriented longitudinal sections through the tumor and including adjacent mucosa are necessary to accurately measure depth of invasion. If the depth is difficult to determine, a best estimate is used. Cutoffs using 0.5 cm and 1.2 cm have yielded better prognostic stratification compared to anatomic level of invasion.³

Even though the anatomic level of invasion and direct invasion into the pancreas, duodenum, gallbladder, colon, stomach, and omentum does not affect the T category, it should be included in the pathology report. Lymphatic or venous invasion does not affect the T category. T4 tumors are characterized by involvement of superior mesenteric artery, celiac axis and/or common hepatic artery. In most instances, these tumors are considered unresectable and hence T4 category is determined by radiologic studies and is not usually assigned by pathologists.

N Category Considerations

The regional nodes for distal bile duct carcinomas are the same as those for carcinomas of the pancreatic head and include the following: lymph nodes along the common bile duct, and hepatic artery; posterior and anterior pancreaticoduodenal nodes; and nodes along the right lateral wall of the superior mesenteric artery.

Tumor involvement of other nodal groups is considered distant metastasis. Anatomic division of regional lymph nodes is not necessary, but separately submitted lymph nodes should be reported as submitted. A minimum number of lymph nodes examined for accurate staging has not been determined, but examination of at least 12 lymph nodes is suggested.^{3,6}

Routine assessment of regional lymph nodes is limited to conventional pathologic techniques (gross assessment and histologic examination), and data are currently insufficient to recommend special measures to detect micrometastasis or isolated tumor cells. Thus, neither multiple levels of paraffin blocks nor the use of special/ancillary techniques, such as immunohistochemistry, are recommended for routine examination of regional lymph nodes.

References

1. DeOliveira ML, Cunningham SC, Cameron JL, et al. Cholangiocarcinoma: thirty-one-year experience with 564 patients at a single institution. *Ann Surg.* 2007;245(5):755-762.
2. Hong SM, Cho H, Lee OJ, Ro JY. The number of metastatic lymph nodes in extrahepatic bile duct carcinoma as a prognostic factor. *Am J Surg Pathol.* 2005;29(9):1177-1183. [erratum in *Am J Surg Pathol.* 2005;29(11):1548.]
3. Amin MB, Edge SB, Greene FL, et al, eds. *AJCC Cancer Staging Manual.* 8th ed. New York, NY: Springer; 2017.
4. Hong SM, Cho H, Moskaluk CA, Yu E. Measurement of the invasion depth of extrahepatic bile duct carcinoma: an alternative method overcoming the current T classification problems of the AJCC staging system. *Am J Surg Pathol.* 2007;31(2):199-206.
5. Hong S-M, Pawlik TM, Cho H, et al. Depth of tumor invasion better predicts prognosis than the current American Joint Committee on Cancer T classification for distal bile duct carcinoma. *Surgery.* 2009;146(2):250-257.
6. Adsay NV, Basturk O, Altinel D, et al. The number of lymph nodes identified in a simple pancreatoduodenectomy specimen: comparison of conventional vs orange-peeling approach in pathologic assessment. *Mod Pathol.* 2009;22(1):107-112.

H. Additional Findings

Chronic inflammatory conditions affecting the bile ducts are associated with higher risk for biliary tract carcinomas. The most common risk factor for cholangiocarcinoma of the extrahepatic bile ducts in Western countries is primary sclerosing cholangitis (PSC), characterized by multifocal strictures and inflammation of the extrahepatic and intrahepatic biliary tree. Patients with PSC are at risk for multifocal biliary carcinomas. In Japan and Southeast Asia, hepatolithiasis due to recurrent pyogenic cholangitis with biliary stones is a more common risk factor for biliary malignancy. Biliary parasites such as *Clonorchis sinensis* and *Opisthorchis viverrini*, prevalent in parts of Asia, are also associated with carcinomas of the extrahepatic bile ducts.